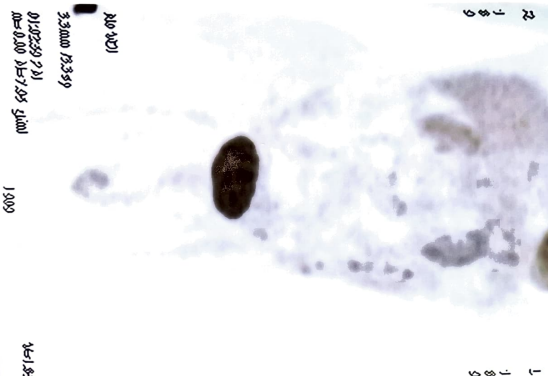


Volume 2
 SR: 300933
 SR:12
 MR:0.00
 DR:OV:20.4cm
 DFOV:37.8cm

S. KRISHNASWAMY R, 149265 MR
 Ramabhisma Hospital, Coimbatore
 A971323

DOB: Dec 24 1937
 EAPW: 27 2005



L R
 1 7
 8 0
 9

Volume 2: Volume 1
 Coronal
 ER: 50% 30633 / 150% 30633

S. KRISHNASWAMY R, 149265 MR
 Ramabhisma Hospital, Coimbatore
 A971323

DOB: Dec 24 1937
 EAPW: 27 2005

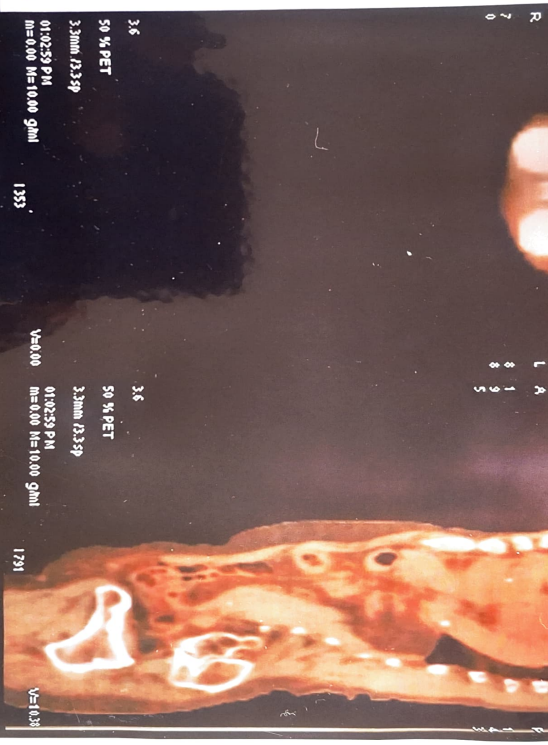


L A
 8 1
 8 9
 5

Volume 2: Volume 1
 Sagittal
 ER: 50% 30633 / 150% 30633

S. KRISHNASWAMY R, 149265 MR
 Ramabhisma Hospital, Coimbatore
 A971323

DOB: Dec 24 1937
 EAPW: 27 2005



3.6
 50 % PET
 3.3min / 23.39
 m=0.00 H=10.00 g/ml

3.6
 50 % PET
 3.3min / 23.39
 m=0.00 H=10.00 g/ml

1791
 V=10.12

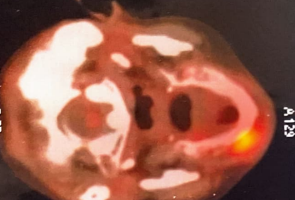
Volume 2: Volume 1

SR:12/13
 L: 1103.5
 MR: 50
 DR:OV:20.4cm

3.3min / 23.39P
 01:02:59 PM
 m=0.00 H=10.00 g/ml

Volume 2: Volume 1
 Axial
 ER: 50% 30633 / 150% 30633

SR:12/13
 L: 1133.2
 MR: 53
 DR:OV:20.4cm
 10 % PET



A129

KRISHNASWAMY R, 149265 MR
 Ramabhisma Hospital, Coimbatore
 A971323


DOB: Dec 24 1937
 EAPW: 27 2005

L
 2
 0
 4

V=6.89

Volume 2: Volume 1
 Axial
 ER: 50% 30633 / 150% 30633

SR:12/13
 L: 1123.0
 MR: 56
 DR:OV:20.4cm
 10 % PET



A129

KRISHNASWAMY R, 149265 MR
 Ramabhisma Hospital, Coimbatore
 A971323

DOB: Dec 24 1937
 EAPW: 27 2005

L
 1
 2

V=10.12

Volume 2: Volume 1
 Axial
 ER: 50% 30633 / 150% 30633

SR:12/13
 L: 1123.0
 MR: 56
 DR:OV:20.4cm
 10 % PET



A129

KRISHNASWAMY R, 149265 MR
 Ramabhisma Hospital, Coimbatore
 A971323

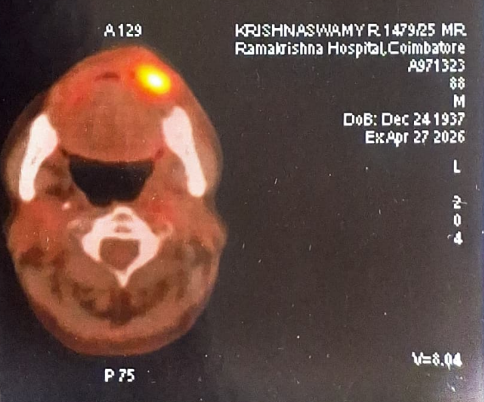
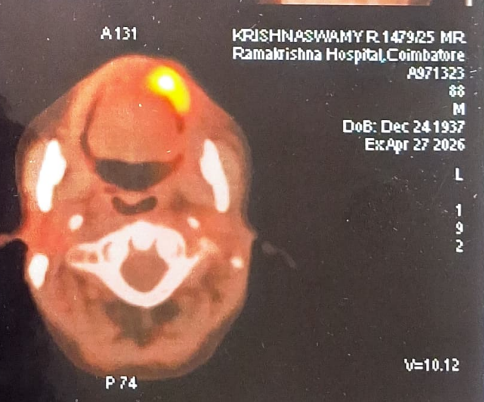
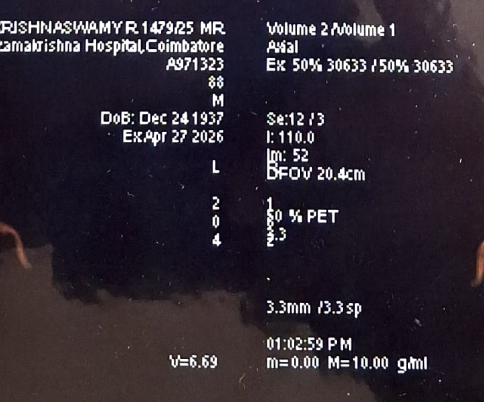
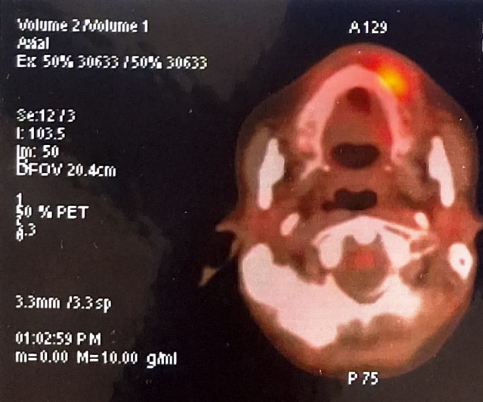
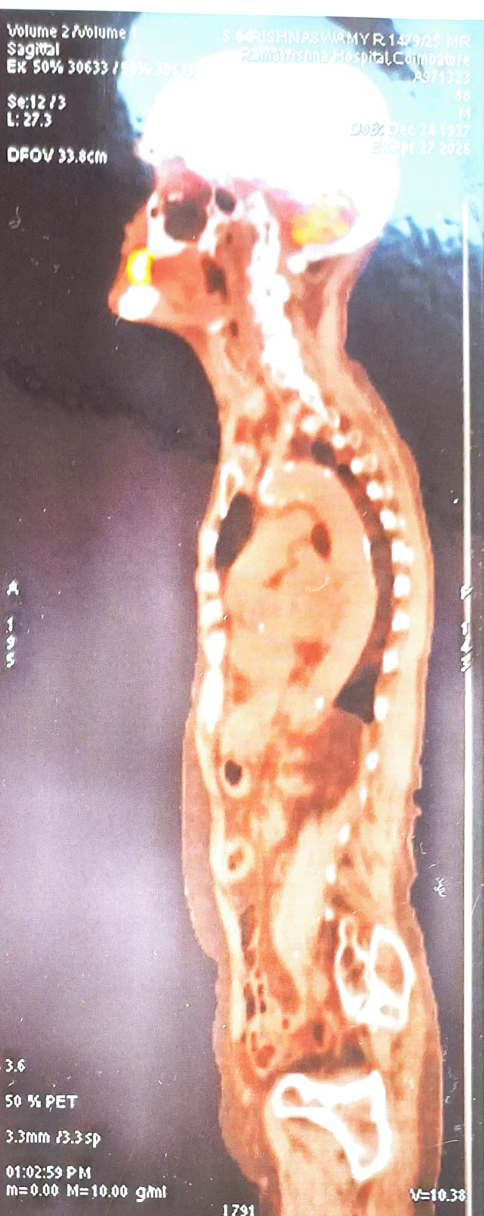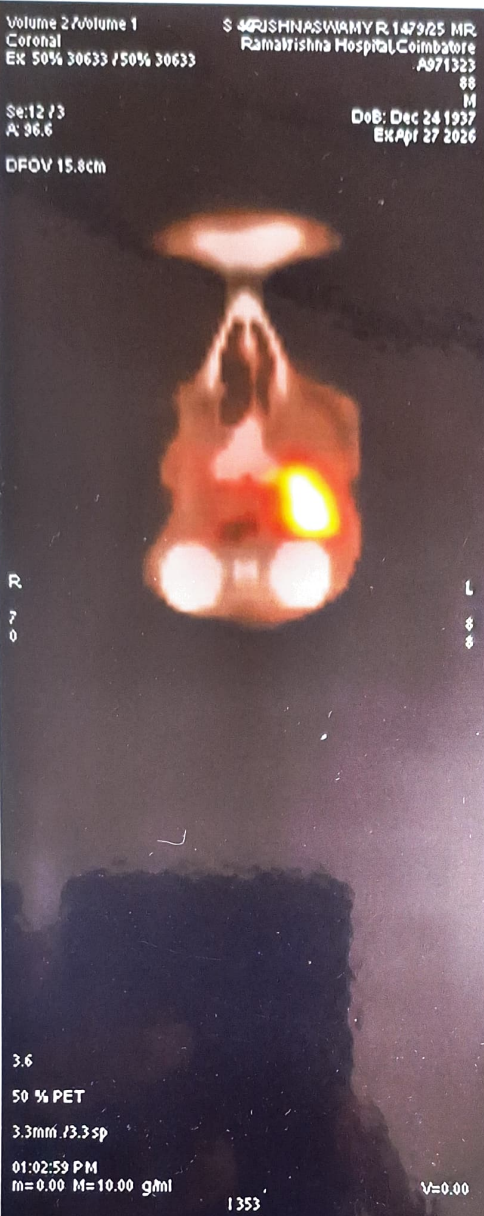
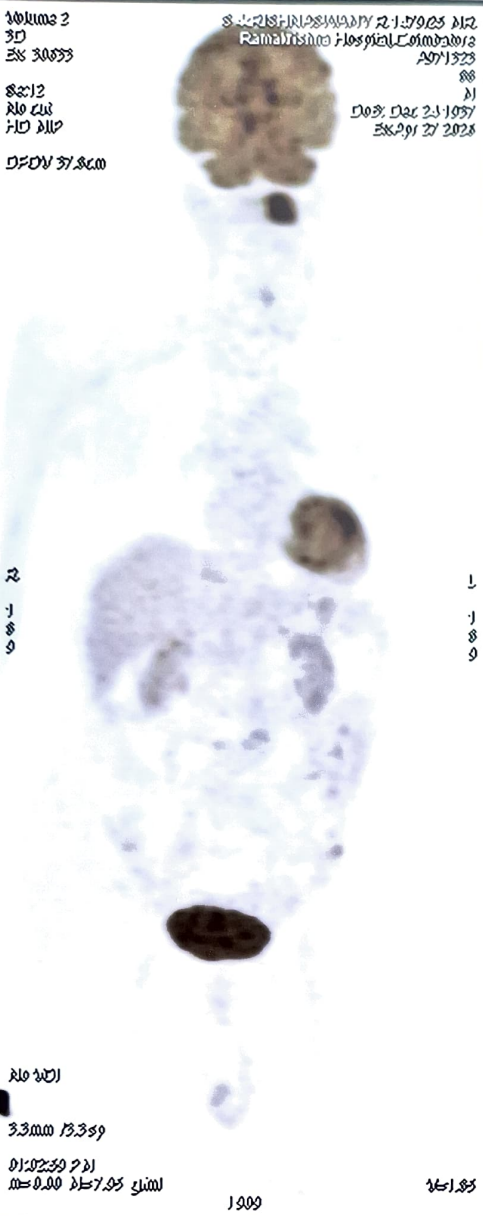
DOB: Dec 24 1937
 EAPW: 27 2005

L
 2
 4

V=10.12

Volume 2: Volume 1
 Axial
 ER: 50% 30633 / 150% 30633

SR:12/13
 L: 1123.0
 MR: 56
 DR:OV:20.4cm
 10 % PET





Sri Ramakrishna Hospital (Multi-Speciality)

395, Sarojini Naidu Road, Sidhapudur, Coimbatore

Ph : 0422 - 4500000, Ext : 2818, 2819, 2820.

petctramakrishnahospital@gmail.com, www.sriramakrishnahospital.com



PET CT REPORT

Page 2 of 3

- Linear atelectasis seen in right lung middle lobe. Fibrotic strands seen in right lower lobe.
- No significant pleural thickening / pleural effusion.
- No significant mediastinal / hilar / axillary lymphadenopathy.
- Ulcerated plaque seen in the aortic arch.
- Cardiomegaly noted.

Abdomen and Pelvis:

- Physiological tracer uptake is noted in the bowel, kidneys and urinary bladder.
- Non FDG avid tiny cyst seen in left kidney.
- Liver, gallbladder, spleen, pancreas, adrenals and right kidney are unremarkable. No focal mass lesion / abnormal FDG uptake.
- Stomach, small and large intestines are unremarkable.
- Prostate gland is unremarkable.
- No significant abdominal / pelvic lymphadenopathy.

Skeleton:

- Grade II spondylolisthesis of L4 over L5 vertebra with facet arthrosis noted.
- Degenerative changes are noted in the spine.
- No focal destructive lesion / abnormal FDG uptake

IMPRESSION:

H/o Carcinoma left buccal mucosa – post treatment, for evaluation

- **Hypermetabolic primary malignancy of left buccal mucosa – residual active disease.**
- **No evidence of metabolically active disease elsewhere in the present scan.**

Compared to the previous PET CT dated 14.10.2025 the present scan shows partial metabolic response


Dr. Arun Ramraj
Consultant Radiologist


Dr. B. Nageswararaj
Consultant Nuclear Medicine

DR. B. NAGESWARARAJ, M.B.B.S, DMRT, DRM
Consultant Nuclear Medicine
Regd No : 60022

27.04.2026

Mr. Krishnaswamy.R



Sri Ramakrishna Hospital

M/s. SNR Sons Charitable Trust Coimbatore - 641 044. Ph : 0422 - 4500000 www.sriramakrishnahospital.com
GSTIN No : 33AABTS1080P1ZA



OUTPATIENT CASH BILL OF SUPPLY



Patient Name	: Mr KRISHNASWAMY R 1479/25 S/O RANGASWAMY	Bill No	: OPCS26206117
Patient ID	: A971323	Bill Date	: 25-04-2026 10:23 AM
OP No	: O260432857	Age / Gender	: 88 Y 4 M 1 D / Male
Payor Name	: SELF PAY	Token No	:
Mobile No	: 9442191692		
Address	: NO-92/2A, KAMBAR STREET, SIVANPURAM COLONY, METTUPALAYAM, TAMIL NADU, INDIA		

Doctor Particulars	Amount	Billed By
Dr. KARTHIKESH M.S., DNB., M.Ch[ONCO],FRCS	500.00	21940

Received with thanks a sum of Rs.500.0/- only / Payment type - Cash



Sri Ramakrishna Hospital

M/s. SNR Sons Charitable Trust Coimbatore - 641 044. Ph : 0422 - 4500000 www.sriramakrishnahospital.com
GSTIN No : 33AABTS1080P1ZA



Patient Name	: Mr KRISHNASWAMY R 1479/25 S/O RANGASWAMY	Bill No	: OPCS26206117
Patient ID	: A971323	Bill Date	: 25-04-2026 10:23 AM
Age / Gender	: 88 Y 4 M 1 D / Male	IP No	:
Doctor Name	: Dr. KARTHIKESH M.S., DNB., M.Ch[ONCO], FRCS		

DR. MR.

Complaints & Clinical Features : Date of Next Review : / /20

W/O C/O -

Δ CPA (L) Buccal mucosa → post 32 # RT + TT x 2 cycles (05/12/25) of 800mg given (25/1/25)

→ last follow up on

ONE → GC - PPT, PPT, neck - no nodes

LFE → oral cavity - 3x3cm ulcerated lesion

Among (L) BM extending into the lower lip = skin nodules

Provisional Diagnosis :

Entire Plan : Surgery ↓ High risk Advice

29/04/26: Renewed PET-CT : non-metastatic CA Buccal mucosa - PET-CT Whole Body

Advised to review patient for pre-op Tx and - review i Reports.

Pre-anesthetic work-up.

Plan: (L) COMPOSITE RESECTION i FLAP RECONSTRUCTION.

PMMC / FREE FLAP.

Printed Date/Time : 25-04-2026 10:23 AM

Printed By : SANJITHA. B

This OP card is valid for 7 days from today which includes one free revisit. This does not include Sundays and Hospital Holidays