

13

Name : Mr. RAJKUMAR RATHINAVELU

OP Number: AHSHC90440

Bill No: AHS-OCR-204820

Package Information

S.No	Service Type/Service Name	Department
1	ITC PROHEALTH PROGRAM - EXECUTIVE HEALTH CHECK-UP ? CATEGORY B (ABOVE 45 YEARS) MALE	
1	2D-ECHO WITH COLOUR DOPPLER	CARDIOLOGY
2	ALBUMIN - SERUM	BioChemistry
3	ALKALINE PHOSPHATASE - SERUM	BioChemistry
4	ALT(SGPT) - SERUM	BioChemistry
5	ANTI HCV -CMIA	Microbiology
6	AST (SGOT) - SERUM	BioChemistry
7	BILIRUBIN CONJUGATED (DIRECT) - SERUM	BioChemistry
8	BILIRUBIN, TOTAL - SERUM	BioChemistry
9	BLOOD GROUPING AND TYPING (ABO and Rh)	Blood Bank - 2 Services
10	CONSULTATION - DENTAL	Dental
11	CONSULTATION - OPHTHALMOLOGY	Ophthalmology
12	CREATININE - SERUM	BioChemistry
13	ECG	CARDIOLOGY
14	GGTP: GAMMA GLUTAMYL TRANSPEPTIDASE - SERUM	BioChemistry
15	GLUCOSE - SERUM / PLASMA (FASTING)	BioChemistry
16	GLUCOSE - SERUM / PLASMA (POST PRANDIAL)	BioChemistry
17	GLYCOSYLATED HEMOGLOBIN (HBA1C) - WHOLE BLOOD	BioChemistry
18	HBsAg - RAPID	Microbiology
19	HDL CHOLESTEROL - SERUM	BioChemistry
20	HEMOGRAM	Haematology
21	LDL CHOLESTEROL - SERUM (DIRECT LDL)	BioChemistry
22	LIPID PROFILE TEST (PACKAGE)	BioChemistry
23	LIVER FUNCTION TEST (PACKAGE)	BioChemistry
24	PHYSICAL EXAMINATION/CONSULTATION BY INTERNAL MEDICINE SPECIALIST	General Medicine
25	PROSTATIC SPECIFIC ANTIGEN (PSA TOTAL) - SERUM	BioChemistry
26	PROTEIN TOTAL - SERUM	BioChemistry
27	SPIROMETRY (BASIC PULMONARY FUNCTION TEST)	Pulmonary Function Lab
28	STOOL OCCULT BLOOD	Haematology
29	STOOL ROUTINE	Haematology
30	THYROID STIMULATING HORMONE [TSH]	BioChemistry
31	TOTAL CHOLESTEROL - SERUM	BioChemistry
32	TREAD MILL STRESS TEST	CARDIOLOGY
33	TRIGLYCERIDES - SERUM	BioChemistry
34	ULTRASOUND - WHOLE ABDOMEN	Ultrasound Radiology
35	UREA - SERUM / PLASMA	BioChemistry
36	URIC ACID - SERUM	BioChemistry
37	URINE ROUTINE (CUE)	Haematology
38	VITAMIN B12 -SERUM	BioChemistry
39	VLDL CHOLESTEROL - SERUM	BioChemistry
40	X-RAY CHEST PA	X Ray

Amount saved on availing Health Check Package INR 36475.00

Amount saved on availing Health Check Package INR 36475.00

YOUR CLINICAL TEST RESULTS

Mr. RAJKUMAR RATHINAVELU

MALE / 53 Yrs / AHS.0000173412 / AHSHC90440

ITC PROHEALTH PROGRAM - EXECUTIVE HEALTH CHECK-UP - CATEGORY B (ABOVE 45 YEARS) MALE

Date : 23/04/2026

HEMOGRAM

Test Name	Result	Unit	Level	Range
Hemoglobin (Colorimetric-Non-cyanmeth Method)	14.9	g/dL	●	13-17
RBC COUNT (Flowcytometry)	5.03	x(10)12 /l	●	4.5-5.5
Packed cell volume (Calculated)	44.4	%	●	40-50
MCV (Calculated)	88.3	fl	●	83-101
MCH (Calculated)	29.6	pg	●	27-32
MCHC (Calculated)	33.5	g/dl	●	31.5-34.5
Platelet Count (Flowcytometry)	260	x(10)9 /l	●	150-450
WBC Count (Flowcytometry)	7.0	x(10)9 /l	●	4-11
Neutrophils (Flowcytometry/ Microscopy)	62.9	%	●	40-80
ABSOLUTE NEUTROPHIL COUNT	4.4	x(10)9 /l	●	2-7
Lymphocytes (Flowcytometry/ Microscopy)	25.0	%	●	20-40
ALC	1.7	x(10)9 /l	●	1.0-3.0
Monocytes (Flowcytometry/ Microscopy)	8.5	%	●	2-10
ABSOLUTE MONOCYTE COUNT	0.6	x(10)9 /l	●	0.2-1.0
Eosinophils (Flowcytometry/ Microscopy)	3.2	%	●	1-6
ABSOLUTE EOSINOPHIL COUNT	0.2	x(10)9 /l	●	0.02-0.5
Basophils (Flowcytometry/ Microscopy)	0.4	%	●	0-2
ABSOLUTE-BASOPHIL COUNT	0.0	x(10)9 /l	●	0.02-0.1

RBC: (Electrical impedance) Normocytic normochromic.
No NRBC's seen.

WBC: (Electrical impedance) Normal in number, distribution and morphology.
No atypical cells/blasts seen.

Platelets: (Electrical impedance) Are adequate in number and have normal morphology.
No hemoparasites seen.

Impression NORMOCYTIC NORMOCHROMIC BLOOD PICTURE

● Within Normal Range ● Boderline High/Low ● Outside Range

YOUR CLINICAL TEST RESULTS

Mr. RAJKUMAR RATHINAVELU

MALE / 53 Yrs / AHS.0000173412 / AHSHC90440

ITC PROHEALTH PROGRAM - EXECUTIVE HEALTH CHECK-UP - CATEGORY B (ABOVE 45 YEARS) MALE

Date : 23/04/2026

ERYTHROCYTE SEDIMENTATION RATE (ESR) [Capillary photometry]	02	mm/1st hr	●	0-10
---	----	-----------	---	------

URINE ROUTINE (CUE)

Test Name	Result	Unit	Level	Range
Color : (Physical examination)	PALE YELLOW			
Color : (Physical examination)	PALE YELLOW			Yellow
Volume : (Physical examination)	30	ml		
Appearance (Physical examination)	CLEAR			Clear
pH (Double indicator- Automated)	6.0			
Specific Gravity (Pka change- Automated)	1.015			
Protein : (Protein error of indicator- Automated)	NEGATIVE			NEGATIVE
Glucose: (GOD-POD - Automated)	NEGATIVE			NEGATIVE
Ketone (Rothera - Automated)	NEGATIVE			NEGATIVE
Bile Pigments: (Diazotization-Automated)	NEGATIVE			NEGATIVE
Urobilinogen (Ehrlich reaction- Automated)	NORMAL			0.3 - 1.0
Blood : (Peroxidase-Automated)	NEGATIVE			NEGATIVE
Nitrate: (Greiss reaction- Automated)	NEGATIVE			NEGATIVE
Leucocyte Esterases (Hydrolysis - Automated)	NEGATIVE			NEGATIVE
RBC (Microscopy)	Nil	Cells/hpf		0 - 2
Pus Cells (Microscopy)	2-4 /h.p.f	/HPF		0 - 5
Epithelial Cells (Microscopy)	2-4 /h.p.f			Occasional - Few
Casts: (Microscopy)	NIL			
Crystals: (Microscopy)	NIL			

BLOOD GROUPING AND TYPING (ABO and Rh)

Test Name	Result	Unit	Level	Range
	● Within Normal Range	● Boderline High/Low	● Outside Range	

YOUR CLINICAL TEST RESULTS

Mr. RAJKUMAR RATHINAVELU

MALE / 53 Yrs / AHS.0000173412 / AHSHC90440

ITC PROHEALTH PROGRAM - EXECUTIVE HEALTH CHECK-UP - CATEGORY B (ABOVE 45 YEARS) MALE

Date : 23/04/2026

BLOOD GROUP	A
Rh (D) Type:	POSITIVE
Method:	COLUMN AGGLUTINATION

LIVER FUNCTION TEST (PACKAGE)

Test Name	Result	Unit	Level	Range
ALT(SGPT) - SERUM	17	U/L	●	5-50
ALBUMIN - SERUM	4.5	g/dL	●	3.5-5.2
GLOBULIN - SERUM - CALCULATED	2.2	g/dL	●	2.0-4.0
ALBUMIN:GLOBULIN (RATIO) - CALCULATED	2.0		●	0.8-2.0
ALKALINE PHOSPHATASE - SERUM	74.1	U/L	●	30.0-120.0
AST (SGOT) - SERUM	22	U/L	●	5-50
BILIRUBIN, TOTAL - SERUM	0.68	mg/dL	●	0.30-1.20

LIPID PROFILE TEST (PACKAGE)

Test Name	Result	Unit	Level	Range
Total Cholesterol	240 *	mg/dL	●	0-200

CREATININE - SERUM

Test Name	Result	Unit	Level	Range
CREATININE - SERUM	0.87	mg/dL	●	0.72-1.18

LIVER FUNCTION TEST (PACKAGE)

Test Name	Result	Unit	Level	Range
GGTP: GAMMA GLUTAMYL TRANSPEPTIDASE - SERUM	21	U/L	●	10-55

GLUCOSE - SERUM / PLASMA (FASTING)

Test Name	Result	Unit	Level	Range
Glucose - Plasma (Fasting)	109 *	mg/dL	●	74-100

● Within Normal Range ● Borderline High/Low ● Outside Range

YOUR CLINICAL TEST RESULTS

Mr. RAJKUMAR RATHINAVELU

MALE / 53 Yrs / AHS.0000173412 / AHSHC90440

ITC PROHEALTH PROGRAM - EXECUTIVE HEALTH CHECK-UP - CATEGORY B (ABOVE 45 YEARS) MALE

Date : 23/04/2026

GLUCOSE - SERUM / PLASMA (POST PRANDIAL)

Test Name	Result	Unit	Level	Range
Glucose - Plasma (POST PRANDIAL)	97	mg/dL	●	80-140

GLYCOSYLATED HEMOGLOBIN (HBA1C) - WHOLE BLOOD

Test Name	Result	Unit	Level	Range
Glycosylated Hemoglobin (HbA1c)	5.1	%	●	4.0-6.0

LIPID PROFILE TEST (PACKAGE)

Test Name	Result	Unit	Level	Range
HDL CHOLESTEROL - SERUM	48	mg/dL	●	"Low : <40High: >59"
LDL Cholesterol (Direct LDL)	159 *	mg/dL	●	0-100

LIVER FUNCTION TEST (PACKAGE)

Test Name	Result	Unit	Level	Range
PROTEIN TOTAL - SERUM	6.7	g/dL	●	6.3-8.1

LIPID PROFILE TEST (PACKAGE)

Test Name	Result	Unit	Level	Range
Triglycerides - Serum	149	mg/dL	●	0-150
TOTAL CHOLESTEROL/HDL CHOLESTEROL RATIO(Calculated)	5.0		●	0.0-100

THYROID STIMULATING HORMONE [TSH]

Test Name	Result	Unit	Level	Range
THYROID STIMULATING HORMONE [TSH]	12.00 *	µIU/mL	●	Normal Biological Reference Interval(TSH): 0.35-4.94

UREA - SERUM / PLASMA

Test Name	Result	Unit	Level	Range
UREA - SERUM / PLASMA	22	mg/dL	●	17-43

URIC ACID - SERUM

● Within Normal Range ● Borderline High/Low ● Outside Range

YOUR CLINICAL TEST RESULTS

Mr. RAJKUMAR RATHINAVELU

MALE / 53 Yrs / AHS.0000173412 / AHSHC90440

ITC PROHEALTH PROGRAM - EXECUTIVE HEALTH CHECK-UP - CATEGORY B (ABOVE 45 YEARS) MALE

Date: 23/04/2026

Test Name	Result	Unit	Level	Range
URIC ACID - SERUM	6.6	mg/dL	●	3.50-7.20

VITAMIN B12 -SERUM

Test Name	Result	Unit	Level	Range
VITAMIN B12 -SERUM	228	pg/ml	●	180-914

LIPID PROFILE TEST (PACKAGE)

Test Name	Result	Unit	Level	Range
VLDL CHOLESTEROL - SERUM:	30	mg/dl	●	10-35

LIVER FUNCTION TEST (PACKAGE)

Test Name	Result	Unit	Level	Range
BILIRUBIN CONJUGATED (DIRECT) - SERUM	0.12	mg/dL	●	0.00-0.40
BILIRUBIN INDIRECT - SERUM - CALCULATED	0.56	mg/dL	●	0.10-1.00

PROSTATIC SPECIFIC ANTIGEN (PSA TOTAL) - SERUM

Test Name	Result	Unit	Level	Range
PROSTATIC SPECIFIC ANTIGEN (PSA TOTAL) - SERUM	0.8	ng/mL	●	0.0-4.0

ANTI HCV -CMIA

Test Name	Result	Unit	Level	Range
ANTI HCV -CMIA	Non Reactive (0.07)			

HBsAg - RAPID

Test Name	Result	Unit	Level	Range
HBsAg	Non Reactive			

ULTRASOUND - WHOLE ABDOMEN

IMPRESSION:

No significant abnormality detected.

● Within Normal Range ● Boderline High/Low ● Outside Range

YOUR CLINICAL TEST RESULTS

Mr. RAJKUMAR RATHINAVELU

MALE / 53 Yrs / AHS.0000173412 / AHS HC90440

ITC PROHEALTH PROGRAM - EXECUTIVE HEALTH CHECK-UP – CATEGORY B (ABOVE 45 YEARS) MALE

Date : 23/04/2026

TREAD MILL STRESS TEST

TMT is negative for inducible ischemia

X-RAY CHEST PA

IMPRESSION:

No significant abnormality noted on the chest radiograph.

2D-ECHO WITH COLOUR DOPPLER

NO REGIONAL WALL MOTION ABNORMALITY OF LV AT REST

NORMAL LV SYSTOLIC FUNCTION

NO LV DIASTOLIC DYSFUNCTION

NO LV CLOT / VEGETATION / PE / COA / PAH

● Within Normal Range ● Boderline High/Low ● Outside Range

APOLLO HOSPITALS ENTERPRISE LIMITED
PRINTED IN USA
Technician: MR.V.N.PATHI

AH-QF-RD-04

DEPARTMENT OF RADIOLOGY

Patients details	RAJKUMAR RATHINAVELU	Age & Sex	53 Years & M
UHID	AHS.0000173412	Ward/Bed No.	AHC
I.P.No./Bill No.	AHSHC90440	Received on	23-Apr-2026
DRN	10391.226046068	Reported on	23-Apr-2026 11:33:03 AM
Referring Doctor	Nithin K P AHC		

ULTRASOUND ABDOMEN AND PELVIS

Clinical information: Health checkup.

FINDINGS:

Liver appears normal in size, shape and echopattern measuring ~ 12.6 cm. No focal parenchymal lesions identified. No evidence of intra/extrahepatic biliary tree dilatation noted. Portal vein appears to be of normal size.

Gallbladder is moderately distended. No definite calculi identified. No evidence of abnormal wall thickening noted. CBD is normal.

Spleen appears normal in size, shape and echopattern measuring ~ 8.8 cm. No focal parenchymal lesions identified.

Visualized portion of pancreas appears normal in size, shape and echopattern. No definite calcification or ductal dilatation noted.

Both kidneys appear normal in size, shape and echopattern. Corticomedullary differentiation appears maintained. No evidence of calculi or hydronephrosis seen on either side.

Right kidney measures ~ 10.2 x 5.5 cm.

Left kidney measures ~ 11.2 x 5.5 cm.

Urinary bladder distended and appears normal. No evidence of abnormal wall thickening noted.

Prostate appears normal in size. Normal echopattern noted within the gland.

No evidence of ascites seen.

IMPRESSION:

No significant abnormality detected.

Dr. Rame Gowda
Radiology

Dept. Of Radiology & Imaging

—END OF THE REPORT—

AH-QF-RD-04

DEPARTMENT OF RADIOLOGY

Patients details	RAJKUMAR RATHINAVELU	Age & Sex	53 Years & M
UHID	AHS.0000173412	Ward/Bed No.	AHC
I.P.No./Bill No.	AHSHC90440	Received on	23-Apr-2026
DRN	10391.126058415	Reported on	23-Apr-2026 11:02:59 AM
Referring Doctor	Nithin K P AHC		

X-RAY CHEST – PA VIEW

X-ray no: 1296

Clinical Information: Health checkup.

FINDINGS

- Lung fields are clear.
- Cardia appears normal.
- Costophrenic angles appear normal on both sides.
- Domes of the diaphragm appear normal.
- Both hila are unremarkable.

=====

IMPRESSION:

No significant abnormality noted on the chest radiograph.

=====


Dr. Rame Gowda

Radiology

Dept. Of Radiology & Imaging

—END OF THE REPORT—

DEPARTMENT OF CARDIOLOGY

Patient Details : Mr. RAJKUMAR RATHINAVELU | Male | 53Yr 10Mth 25Days
UHID : AHS.0000173412 **Patient Location:** AHC
Patient Identifier: AHSHC90440 
DRN : 5626085460 **Completed on :** 23-APR-2026 10:34
Ref Doctor : Dr. Nithin K P AHC

2D-ECHO WITH COLOUR DOPPLER

MEASUREMENTS (M- MODE)

AO :2.3 cms LVID(d):4.72 cms
 LA :3.0 cms LVID(s):3.21 cms
 RVID :1.6 cms IVS (d):1.01 cms
 ESV :42ml IVS (s):1.21 cms
 EDV 102ml PW (d):1.02 cms
 EF :60 % PW (s):1.25 cms

VALVES

Mitral Valve : Normal
 Aortic valve : Normal
 Tricuspid Valve : Normal.
 Pulmonary Valve: Normal.

CHAMBERS

Left Atrium : Normal .
 Right Atrium : Normal.
 Left Ventricle : Normal
 Right Ventricle : Normal.

SEPTAE

IVS : Intact.
 IAS : Intact.

GREAT ARTERIES

Aorta : Normal.
 Pulmonary Artery : Normal.

2D-ECHO WITH COLOUR DOPPLER

DOPPLER DATA

Mitral Valve : E -0.74 m/sec A -0.63 m/sec
Aortic valve : 1.40 m/sec
Tricuspid Valve : Trivial TR Jet Gradient 20 mmHg, PASP 30 mmHg
Pulmonary Valve : 1.02 m/sec

PULMONAR VEINS : Normal

SYSTEMIC VEINS : Normally collapsing IVC on inspiration size 1.2 cm.

WALL MOTION ABNORMALITIES : Absent

PERICARDIUM : Normal

VEGETATION/THROMBUS : Nil

OTHER FINDINGS : Nil

Impression:

NO REGIONAL WALL MOTION ABNORMALITY OF LV AT REST
NORMAL LV SYSTOLIC FUNCTION
NO LV DIASTOLIC DYSFUNCTION
NO LV CLOT / VEGETATION / PE / COA / PAH

— END OF THE REPORT —



Dr Srinivas K.H MBBS,MD,DM

Consultant - Cardiologist

ID: 000090440

23-Apr-2026
11:40:17

Age: 59 years
Height: 176cm
Weight: 68kg
Sex: Male
Med: Nil
DR. K. H. SRINIVAS

BRUCE

Max HR: 143bpm 85% of max predicted 167bpm
Max BP: 150/70
Reason for Termination: Max HR attained

Total Exercise time: 11:30

Maximum workload: 10.4 METS

25.0 mm/s
10.0 mm/mV
100Hz

Test ind: SCREENING FOR CAD

Comments: GOOD EFFORT TOLERANCE
NORMAL HR AND BP RESPONSE
NO ANGINA / ARRHYTHMIA
UPSLOPING ST DEPRESSION
IMP- STRESS TEST NEGATIVE FOR INDUCIBLE ISCHEMIA

Phase Name	Stage Name	Time in Stage	Speed (mph)	Grade (%)	Workload (METS)	HR (bpm)	BP (mmHg)	RPP (x100)
PRETEST	SUPINE	0:07	***	***	1.0	78	120/70	94
	STANDING	0:56	***	***	1.0	74	120/70	89
	HYPERVENT	0:17	1.5	0.0	1.1	85	120/70	102
	STAGE 1	3:00	1.7	10.0	4.6	103	130/70	134
	STAGE 2	3:00	2.5	12.0	7.0	115	130/70	150
EXERCISE	STAGE 3	3:00	3.4	14.0	10.1	131	140/70	183
	STAGE 4	2:30	4.2	16.0	13.4	143	150/70	215
	Post	2:15	***	***	1.0	95	140/70	192
RECOVERY								

To book appointments or Consult doctors online, visit www.asrapol.com

PULMONARY FUNCTION TEST REPORT

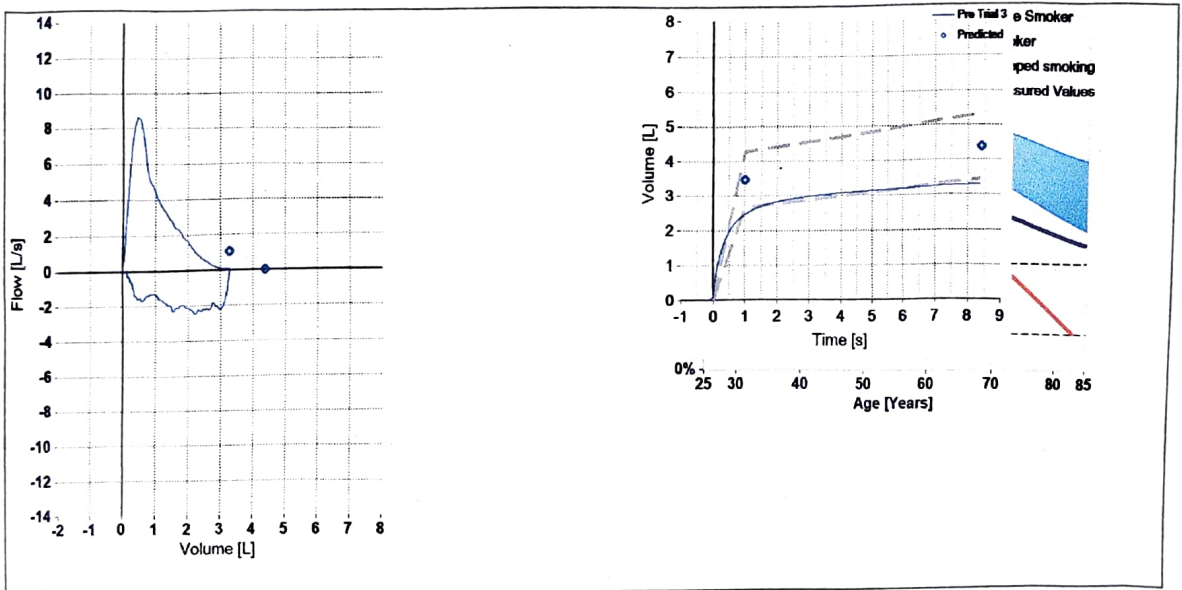
Patient Information

Name	RAJKUMAR , RATHINAVELU	Test Type	FVL (ex/in)
ID	AHS.173412	Test Date	23-04-2026 13:02:04
Age	54	Interpretation	GOLD(2008)/Hardie
Height	176 cm	Predicted	Quanjer (GLI), 2012 * 1.00
Weight	68 kg	Value Selection	Best Trial
Gender	Male	BMI	22
Ethnicity	Asian	Referred by	DR MHC DR MHC
Asthma	No	Technician	
Smoker	Yes ✓		

Pre Best

Parameter	Pred	LLN	Trial 3	%Pred
FVC [L]	4.37	3.43	3.28*	75
FEV1 [L]	3.46	2.66	2.46*	71
FEV1/FVC [%]	79.4	69.0	74.8	94
FEF25-75 [L/s]	3.12	1.61	1.83	59
PEF [L/s]	-	-	8.71	-
FET [s]	-	-	8.4	-
FIVC [L]	4.37	3.43	3.14*	72
PIF [L/s]	-	-	2.47	-

* Indicates value outside normal range or significant post change.



Interpretation :

SPQ2-98%
MILD OBSTRUCTION WITH SMALL AIRWAY OBSTRUCTION ,CORRELATE CLINICALLY

[Signature]
Physician Signature

Name: Mr. Rajkumar Rathinavelu
 Age: 53yr
 Sex: Male
 UHID: AHS: 0000173412

23/4/2026

9164753973

HEALTH CHECK-CASE SHEET

CHIEF COMPLAINT: Patient has come for regular dental check up.

MEDICAL HISTORY: Nil. Habit: Smoking daily - Since 35 yrs.

FINDINGS:

Drug Allergy: Nil.

Caries: DC 

Abrasion: - present

Missing Teeth: -

Calculus: ++ ~~++~~

Impactions: -

Mobility: -

Attrition: - present

Restored Teeth

Root Stumps: 

Others:

87654321	12345678
87654321	12345678

General Spacing noted.

DIAGNOSIS:

X-Ray

IOPA:  Adv. OPG


Treatment Plan:

Angular recession with pocket present

1) Adv. oral prophylaxis - along with periodontal evaluation.

2) Adv. filling on 

5) Adv. Night Guard - for attrition.

3) Adv. extraction 

4) Adv. follow up every 6 months.

S/AS - Dr. Arshad

Mr. RAJKUMAR RATHINAVELU
53y/M

23/4/22

HE

→ No T₂DM / HTN

TC - 240

TSH - 12.00

LDL - 159

P - 74 bpm

BP - 120/80 mmHg

ABH

FT₃, FT₄, Anti TPO antibody.

→ T. THYRONORM 25mcg 1-00 (BKA)
x 1 month

→ Regular physical activity

